Two Recurrent Hernias in a Patient Operated for L4-L5 Disc Herniation: Both Lesions Treated and Cured by Intraforaminal Oxygen-Ozone Administration

C. PIANA

Head, Neuroradiolody Unit, SS Benvenuto e Rocco Hospital; Osimo Ancona, Italy

Key words: discal hernia, lumbar spine, discolysis, medical ozone

SUMMARY - *This paper describes a young woman operated for herniated disc who presented two recurrent hernias at the same level one after the other in the space of a few months. Both lesions were successfully treated by intraforaminal administration of an Oxygen-Ozone gas mixture. The outcome of our patient offers further evidence that oxygen-ozone therapy is a valid alternative to surgery in the treatment of herniated disc disease.*

Material, Method and Case Report

The patient was born on 14th January 1963.

Her history was unremarkable and she had had one pregnancy three years earlier. The patient was tall with normal bone structure and muscle trophism. On 18th November 2001 she experienced acute left sciatica pain with loss of strength in the left leg. Emergency neurological examination disclosed left TA strength deficit [3-5], left EPA and ECD [2-5]. There was no associated sensory deficit.

MR scan on 19th November 2001 reported "... A large left posterolateral herniated disc with compression of the nerve root structures in the preforaminal region ....."

MR examination 19/11/2001 (figure 1)

The patient was urgently admitted to the neurosurgery ward on 21st November 2001 and surgery was performed on 22nd November. The surgical report states: "L4-L5 microdiscectomy via the left interlaminar route. The L5 nerve root appears compressed by an extruded herniation which was removed followed by emptying of the L4-L5 intervertebral disc space. At the end of the surgical procedure the nerve root was free." Pain in the left leg had disappeared on neurological examination prior to discharge on 23rd November 2001 with an almost complete recovery of the left AI strength deficit. As pain persisted in her left leg an EMG of the extremities was performed on 15th December 2001 disclosing: " examined the pedidius, extensor digitorum longus, peroneus longus and left **ela??** muscles; tibialis anterior and left biceps femoris muscle...

Conclusions: signs of left L4(L5) radiculopathy with signs of axonotmesis underway".

For this reason the patient underwent a follow-up MR scan of the lumbar region on 31st December 2001 showing: " ....residues of L4-L5 surgery with mild left anterolateral epidural inhomogeneity due to scarring: there are no signs of hernia recurrence underway ....."

Follow-up MR scan 31/12/2001 before and after i.v. contrast administration (figure 2)

From this point on the patient had alternating phases of well-being and reacutization of pain for several months without strength deficit.

Pain resumed in September 2002 with continuous left sciatic nerve pain. On 11th September 2002 she had another follow-up lumbar MR scan "...At L4-L5 level surgical residues of previous left hemilaminectomy with scarring material in the left lateral epidural region and evidence of left preforaminal posterior disc herniation causing evident compression of the nerve root and congestion of the venous plexus ...".

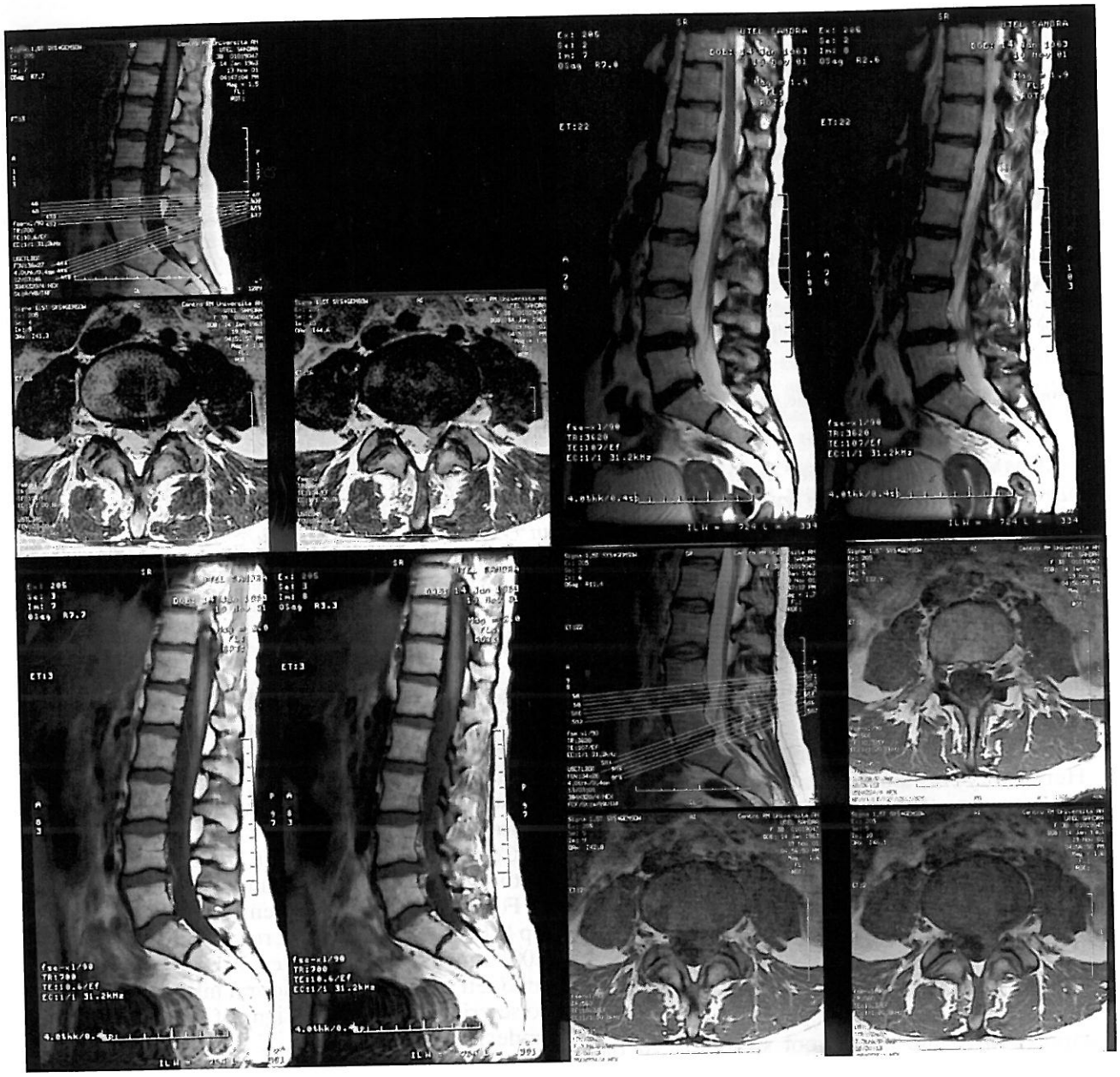

Figure 1 19 November 2001.

MR examination 22/9/2002 (figure 3)

The patient was extremely anxious and alarmed that she could not look after her young child on her own.

She did not want further surgery and therefore received medical management with analgaesics and steroids for several weeks without benefit.

In early November 2002 she agreed to undergo treatment with intraforaminal injection of an oxygen-ozone (O_2-O_3) gas mixture.

She had five weekly sessions of treatment under CT guidance with insertion of two 22G spinal needles intraforaminally to the left and right of the L4-L5 disc space with bilateral administration of 15cc of the O_2-O_3 gas mixture at a concentration of 30 ng/ml (figure 4).

The patient referred a marked regression of pain after the second treatment session. At the end of the treatment cycle the patient was pain-free and had a full recovery of mobility.

Five months after the end of treatment she had a follow-up lumbar MR scan on 6th May 2003 reporting: "…. an objective reduction in size of the left

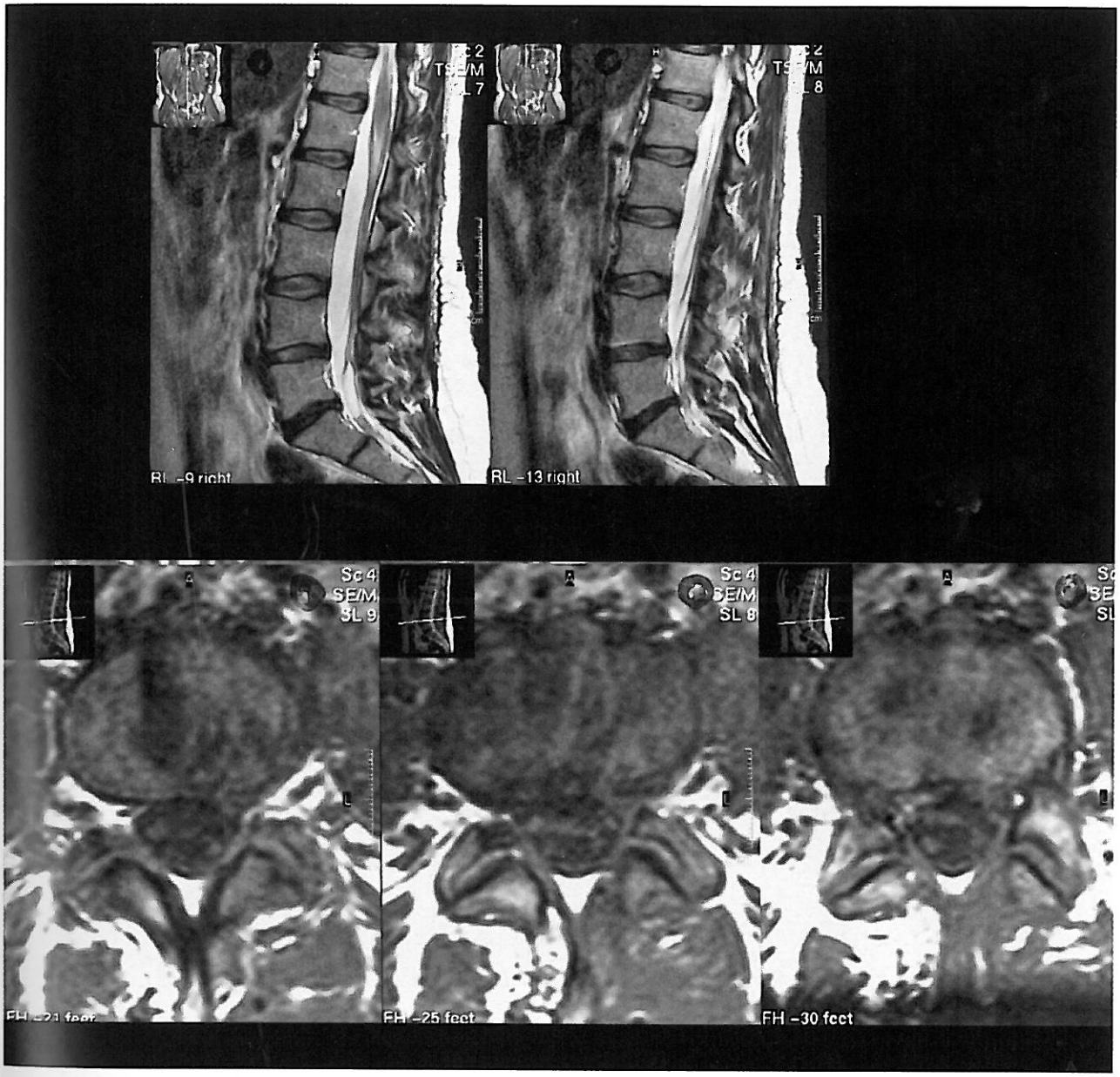

Figure 2 31 December 2001.

preforaminal paramedian herniation previously noted in L4-L5...".

MR examination 6/5/2003 (figure 5)

The patient was well throughout the following summer and autumn. On the advice of the doctor who had performed the O_2-O_3 treatment she had another follow-up MR scan on 13th January 2004 reporting"....in surgical residues at L4-L5 level there is no hernia recurrence in the site of surgery .....".

MR examination 13/1/2004 (figure 6)

At this point the patient had returned to work. Sixteen months later after minor muscular effort she presented a violent left sciatic nerve pain with associated strength deficit.

On 9th June 2005 a further MR follow-up scan disclosed:

"... appearance of left posterolateral herniation at L4-L5 level causing marked compression on the contiguous nerve root structures. This finding was not present in the previous scan .....".

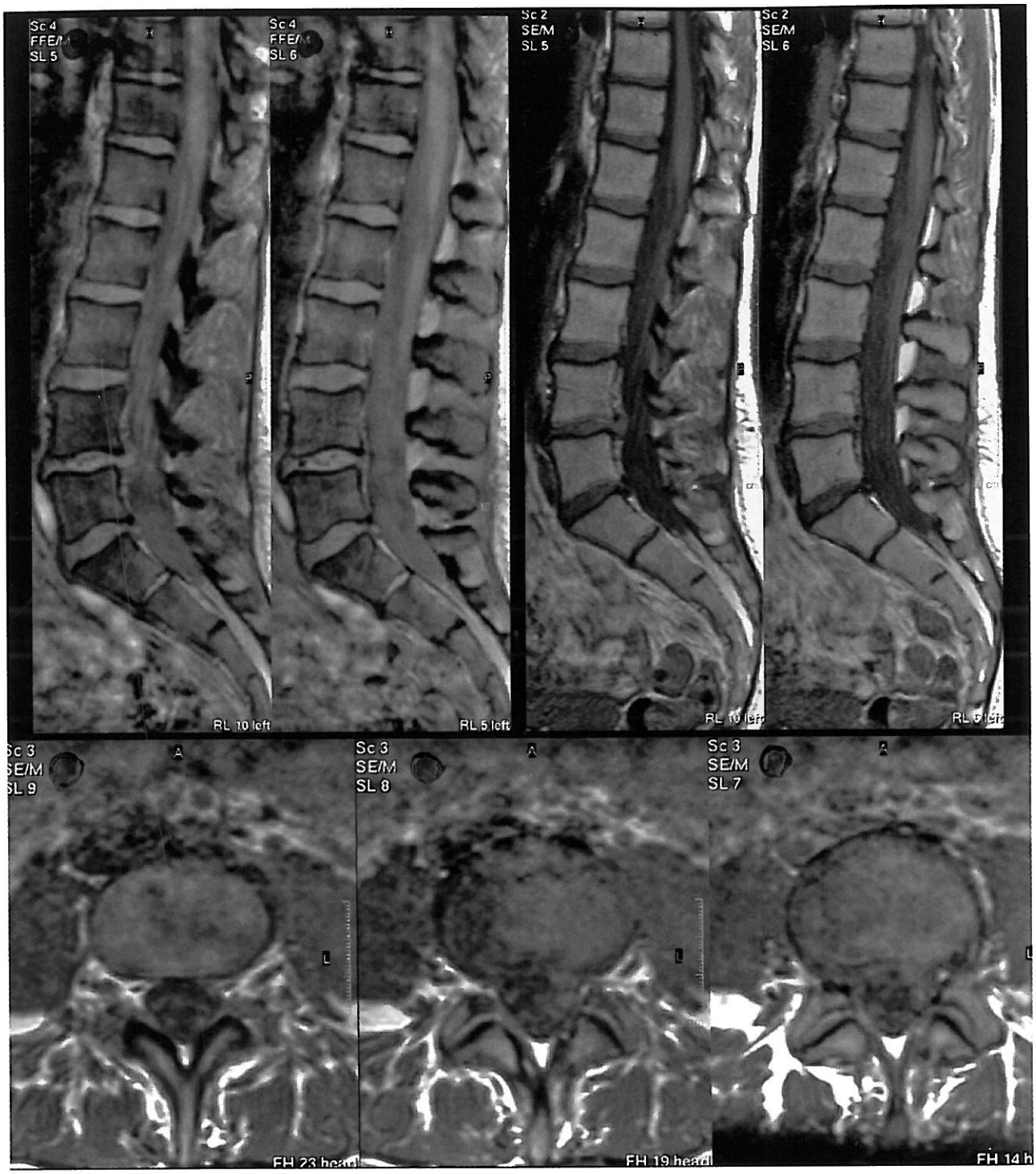

Figure 3A 22 September 2002.

MR examination 9/6/2005 (figure 7)

The patient contacted the ozone therapist again to undergo a further cycle of O_2-O_3 treatment with the same method used previously. After two treatment sessions the patient referred a complete regression of pain and recovery of strength in her left leg. She completed the five treatment sessions. At clinical follow-up three months after the end of the O_2-O_3 treatment the patient referred a complete

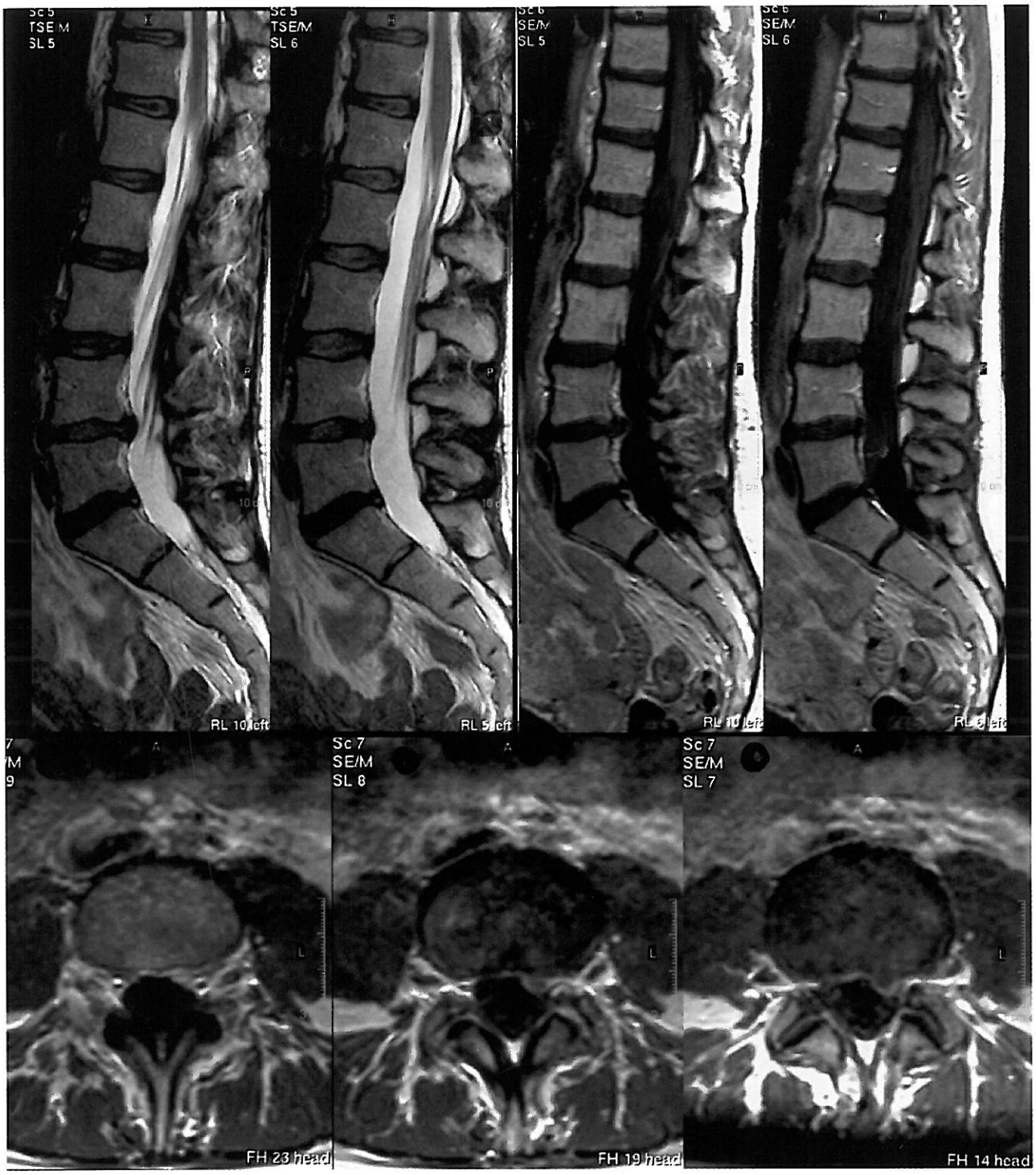

Figure 3B 22 September 2002.

recovery of sensitivity and strength. She decided to have a follow-up MR scan on 21st June 2006 which reported "...a disappearance of the recurrent herniation prevously documented at L4-L5 level. There remains only left interforaminal disc bulging ....".

MR examination 21/6/2006 (figure 8)

The patient is currently well without neurological sensory or strength deficits, with a full recovery of her working activity and social life.

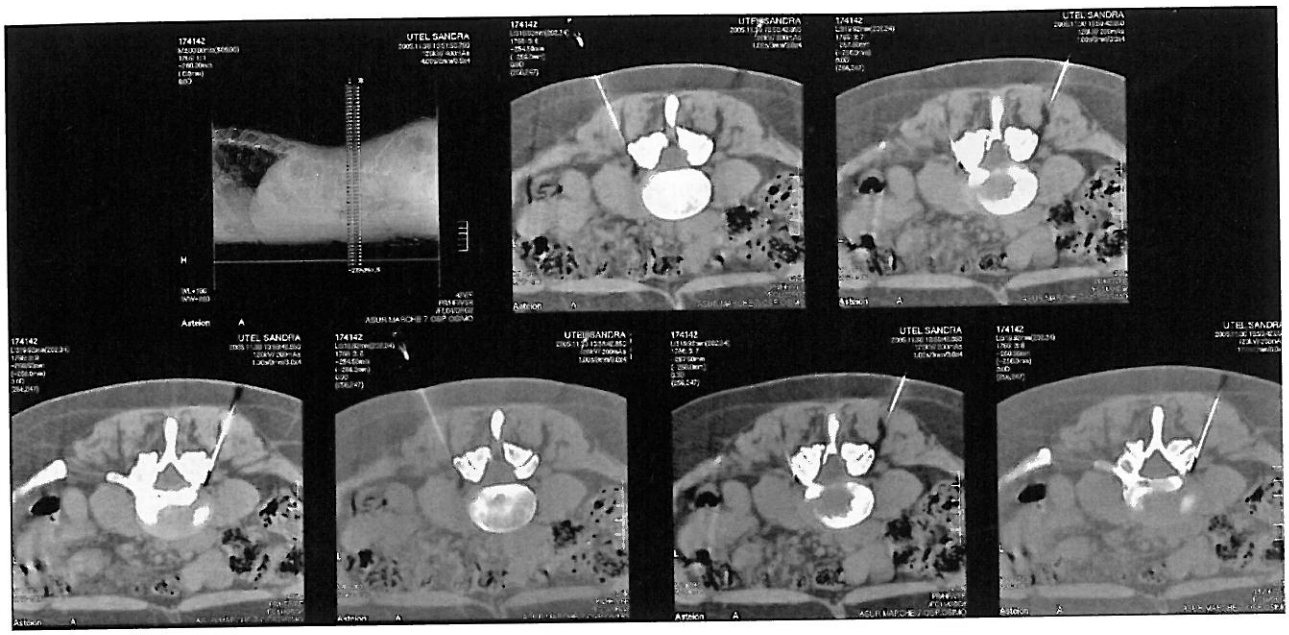

Figure 4 CT examination.

Final Remarks

The clinical course of this patient offers further evidence that the O_2-O_3 administration is a valid treatment for discal disease.

The recurrence of herniated disc so soon after surgery suggests that the lesion to the anulus fibrosus in this patient was particularly severe, leading to partial expulsion of the nucleus pulposus on different occasions. It is hoped that the nucleus pulposus is now completely dehydrated and hence no longer able to generate further recurrences. Having cured the recurrent hernias with O_2-O_3 administration, the surgical damage was limited to one operation.

I hate to think what condition the patient's back would be in had she undergone two further surgical interventions.

References

1 Alexandre A, Soattin GB, Fumo G: Intradiscal ozone injection: new solution for herniated disc problems. Miami Cedars Course for Neurosurgery, Miami 1997.

2 Alexandre A, Fumo G: Discolisi percutanea mediante O_2-O_3 nell'ernia discale lombare. In: Lombalgie e lombosciatalgie. Criteri di diagnosi e cura. Turin Ed Cortina 1998: 367-377.

3 Andreula CF, Simonetti L, De Santis F et Al: Minimally invasive oxigen-ozone therapy for lumbar disk herniation. Am J Neuroradiol 24: 996-1000, 2003.

4 Andreula CF: Ernie discali lombosacrali e patologia degenerative correlata.Trattamento interventistico spinale con chemiodiscolisi con nucleoptesi con O_3 ed infiltrazione periradicolare e periganglionare. Rivista di Neuroradiologia 14: 81-88, 2001.

5 Barbara C, Simonetti L, Giatti S et Al: Trattamento percutaneo dell'ernia discale con iniezione intradiscale di miscela di ozono. Risultati preliminari. Rivista di Neuroradiologia 12: 39, 1999.

6 Bocci V: Does ozone therapy normalize the cellular redox balance? Med Hypotheses 46: 150-154, 1996.



Figure 5A 6 May 2003.

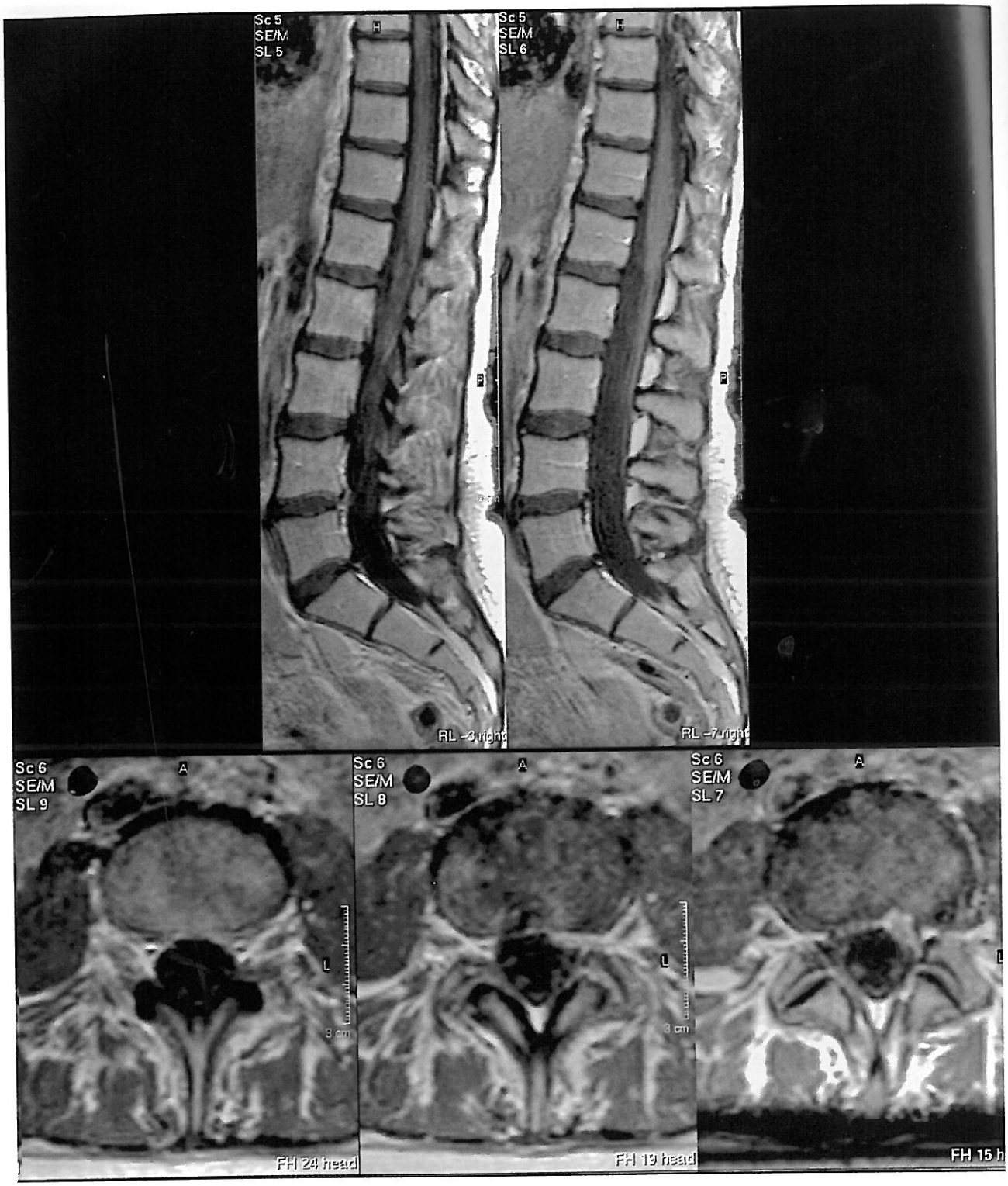

Figure 5B 6 May 2003.

7 Bonetti M, Cotticelli B, Raimondi D et Al: Ossigeno ozono terapia vs infiltrazioni epidurali cortisoniche. Rivista di Neuroradiologia 13; 203-206, 2000.
8 Bonetti M, Cotticelli B, Valdenassi L et Al: Analisi dei risultati dopo trattamento con O_2-O_3 nelle ernie intra ed extraforaminali lombari. Rivista di Neuroradiologia 14: 89-92, 2001.
9 Bonetti M, Cotticeli B, Valdenassi L et Al: La riso-

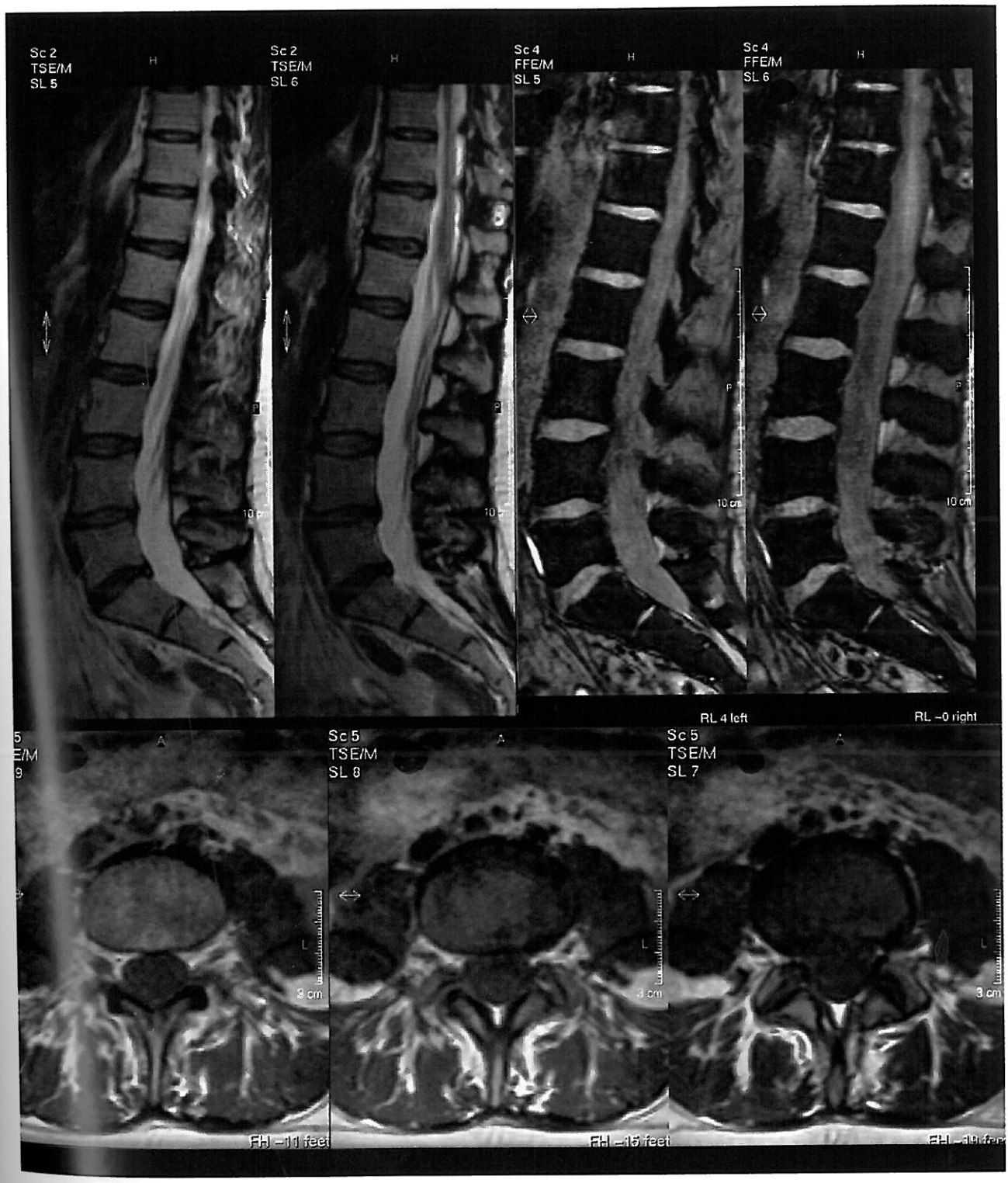

Figure 6 2004.

nanza magnetica nucleare con gadolinio nella valutazione dell'efficacia terapeutica del trattamento con ossigeno-ozono nei conflitti disco-radicolari. Rivista di Neuroradiologia 14: 109-111, 2001.

10 Bonetti M, Valdenassi L: Oxygen-ozone therapy in percutaneous treatment of discal hernias. In atti "Unconventional medicine at the beginning of the third millennium" Pavia 1998. Ed Cost, Bologna 1998.

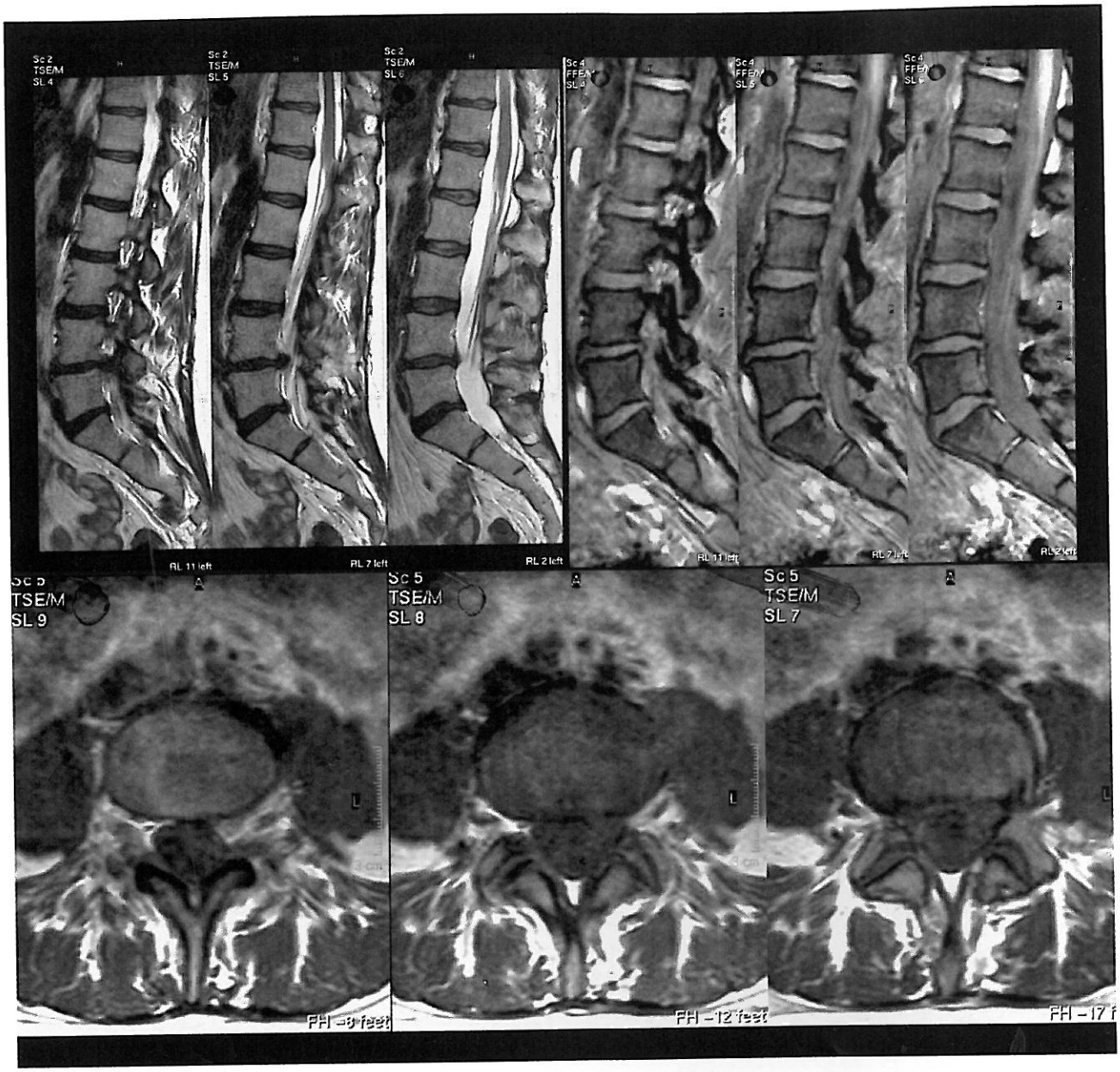

Figure 7A

11 Bonetti M: Tecnica intraforaminale TC giudata. Rivista Italiana di Ossigeno-Ozonoterapia 1: 69-72, 2002.
12 Bozzao A, Gallucci M: Lumbar disc herniation: MR imaging assessment of natural history in a patient treated without surgery. Radiology 185: 135-141, 1992.
13 Brayda-Bruno M, Cinnella P: Il trattamento dell'ernia discale con infiltrazione di ossigeno-ozono in paravertebrale. In "lombalgie e lombosciatalgie: criteri di diagnosi e cura". Ed Libreria Cortina Turin 1998: 361-366.
14 Fabris G, Tommasini G, Lavaroni A et Al: L'ozonoterapia nel trattamento per cutaneo dell'ernia discale lombare. Rivista di Neuroradiologia 12: 23, 1999.
15 Fabris G, Tomassini G, Petralia B et Al: L'ossigeno terapia intraforaminale. Rivista di Neuroradiologia 14: 25-30, 2001.
16 Fabris G: Tecnica intraforaminale con guida fluoroscopica. Rivista Italiana di Ossigeno-Ozonoterapia 1: 63-68, 2002.
17 Greenwood J, McGuire TH, Kimbell F: A study of the causes of failure in the herniated intervertebral disc operation: an analysis of 67 reoperated cases. J Neurosurg 9: 15-20, 1952.
18 Iliakis E: Ozone treatment in low back pain. Orthopaedics 1: 29-33, 1995.
19 Iliakis E: Utilizzo dell'ossigeno-ozonoterapia nella pratica ortopedica Acta Toxicol Ther 2-3: 249-253, 1996.

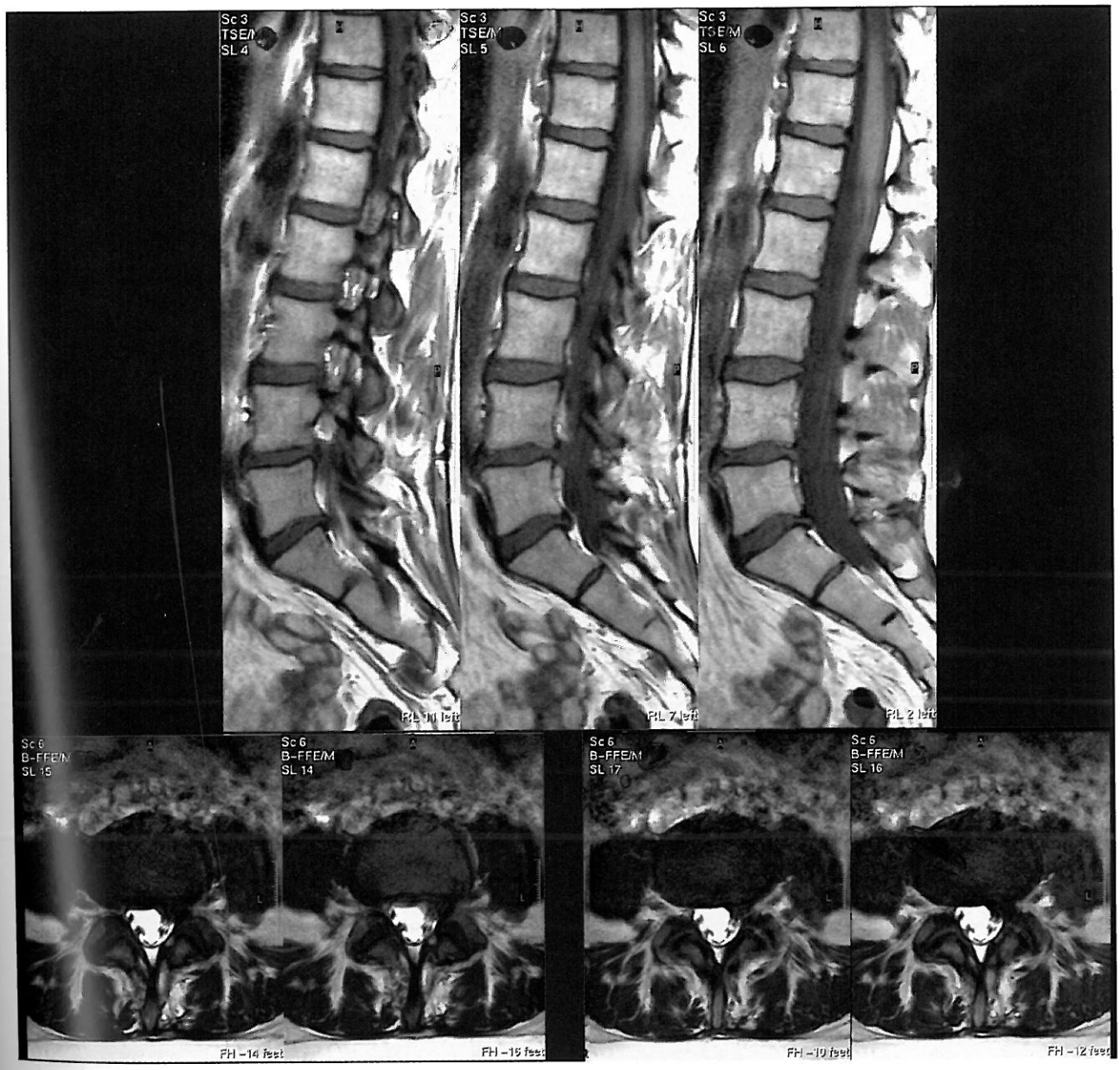

Figure 7B

20 Iliakis E, Valadakis V, Vynios DH et Al: Ratiolazionation of the activity of medical ozone on intervertebral disc and histological and biochemical study. Rivista di Neuroradiologia 14: 25-30, 2001.

21 Law JD, Lehman RW, Kirsc WM: Reoperation after lumbar intervertebral disc surgery. J. Neurosurg 48: 259-263, 1978.

22 Leonardi M, Barbara C, Agati R et Al: Trattamento per cutaneo dell'ernia discale lombare con iniezione intradiscale di miscela di ozono. Rivista di Neuroradiologia 14: 51-53, 2001.

23 Leonardi M, Simonetti L, Barbara C: Effetti dell'ozono sul nucleo polposo: reperti anatomo-patologici su un caso operato. Rivista di Neuroradiologia 14: 57-59, 2001.

24 Leonardi M: La puntura discale sotto guida fluoroscopica. Rivista Italiana di Ossigeno-Ozono Terapia 1: 73-78, 2002.

25 Pheasant HC: Sources of failure in laminectomies. Orthop Clin North Am 1975: 319-329.

26 Rabishong P: Comprehensive approach to the discoradicular conflict. Rivista di Neuroradiologia 10: 515-518, 1997.

27 Richelmi P, Valdenassi L: Aspetti biochimici ed implicazioni tossicologiche in ossigeno-ozonoterapia. Attualità e prospettive in terapia antalgica. Ed ESM 1995: 185-204.

28 Richelmi P, Valdenassi L, Bertè F: Basi farmacologiche dell'azione dell'ossigeno-ozonoterapia. Rivista di Neuroradiologia 14: 17-22, 2001.

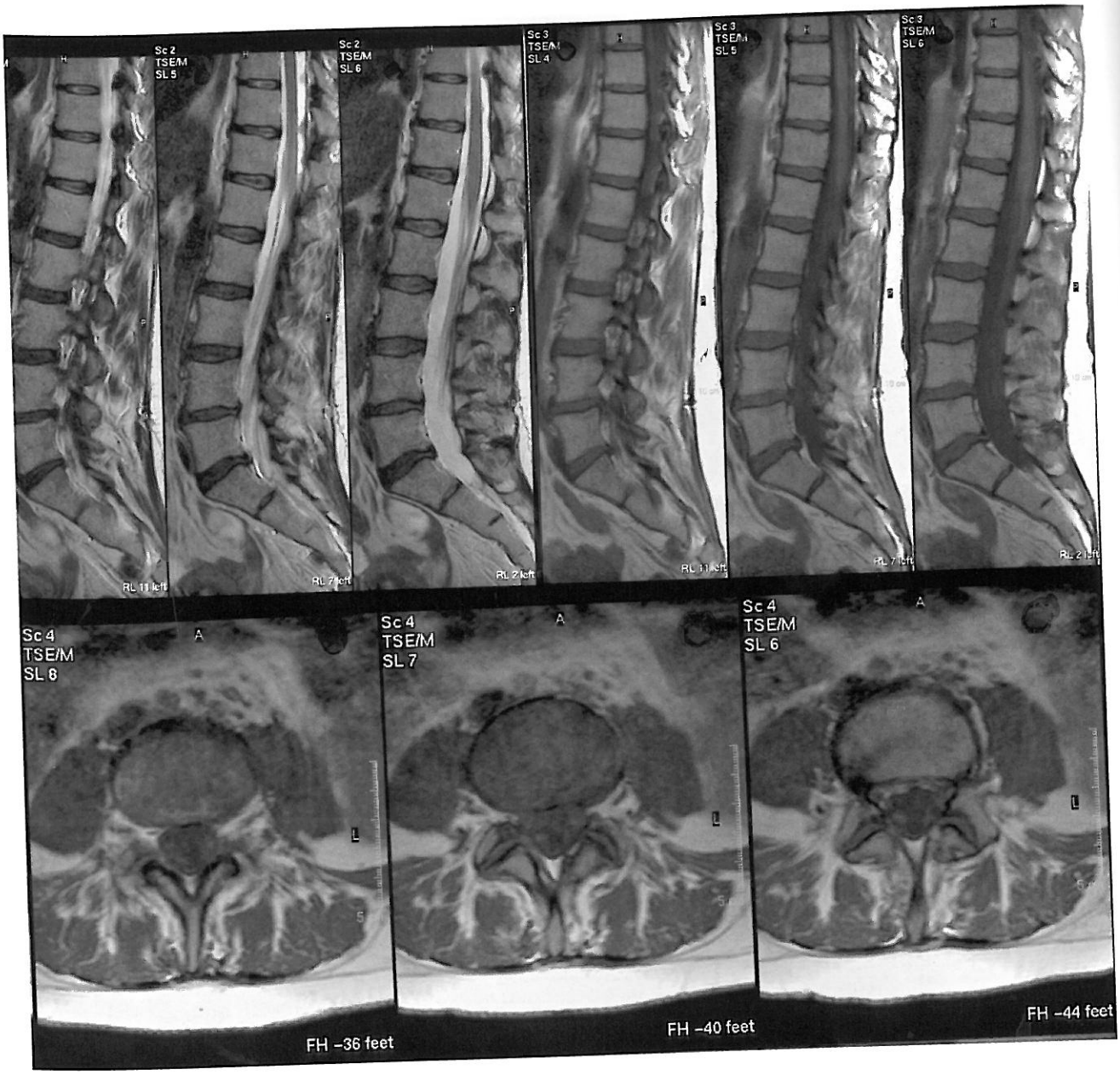

Figure 8 21 June 2006.

29 Scarchilli A: Tre anni di follow-up nel trattamento delle lombalgie e lombosciatalgie con ozono intradiscale. Rivista di Neuroradiologia 14: 39-41, 2001.
30 Splendiani A, Barile A, Gallucci M et Al: Spontaneous signs for prognostic evaluation. Rivista di Neuroradiologia 16: 1367-1370, 2003.

C. Piana, MD
Head, Neuroradiolody Unit
SS Benvenuto e Rocco Hospital
Via Leopardi,15
60027 Osimo (AN)
E-mail: oberch@libero.it